



Newly-Diagnosed Multicentric Pilocytic Astrocytoma: Complete Response and > 22 Years Survival in a Six Year and Nine-Month-Old Female Treated with Antineoplastons

Stanislaw Rajmund Burzynski^{1,*}, Gregory Burzynski¹, Tomasz Janicki¹, Samuel Beenken²

¹Medical Division, Burzynski Clinic, Houston, USA

²Oncology Writings, Calera, USA

Email address:

srb@Burzynskiclinic.com (S. R. Burzynski)

*Corresponding author

To cite this article:

Stanislaw Rajmund Burzynski, Gregory Burzynski, Tomasz Janicki, Samuel Beenken. Newly-Diagnosed Multicentric Pilocytic Astrocytoma: Complete Response and > 22 Years Survival in a Six Year and Nine-Month-Old Female Treated with Antineoplastons. *International Journal of Clinical Oncology and Cancer Research*. Vol. 7, No. 3, 2022, pp. 76-82. doi: 10.11648/j.ijcocr.20220703.15

Received: July 7, 2022; **Accepted:** July 27, 2022; **Published:** August 10, 2022

Abstract: Rationale: Pilocytic astrocytoma (PA) is generally a circumscribed, well-differentiated, slowly-growing tumor, classified as World Health Organization (WHO) grade I. The case of a female child with a newly diagnosed multicentric PA is presented here to detail and discuss the efficacy of Antineoplastons A10 (Atengenal) and AS2-1 (Astugenal) in treatment of this disease. Objectives: The child was treated at the Burzynski Clinic (BC) according to the Phase II protocol, BT-23, which utilized Antineoplastons A10 and AS2-1 (ANP therapy) in the treatment of patients with optic pathway gliomas. ANP therapy was delivered via subclavian catheter and infusion pump. Tumor response was measured by sequential magnetic resonance imaging (MRI) of the brain. Findings: At presentation to the BC, the child complained of blurred vision and right-sided hemianopsia. On physical exam, she was alert and orientated. There was blurring of her right optic disc. Deep tendon reflexes were equal bilaterally with down-going toes. The child's initial brain MRI and subsequent biopsy indicated a multi-centric PA involving the optic chiasm, hypothalamus and left hemisphere. Her parents elected for treatment at the BC. Baseline brain MRI, performed on November 15, 1999, showed three enhancing target lesions with a combined volume of 16.49 cm². Sequential brain MRIs demonstrated that a partial response (PR) and then a complete response (CR) were achieved on April 12, 2000 and June 25, 2003, respectively. Twenty-two years after initiation of ANP therapy, the patient is doing well and showing no evidence of recurrent disease. Conclusions: The utilization of ANP therapy to obtain a cure of newly diagnosed multicentric PA in a female child is presented. We conclude that ANP therapy is an attractive therapeutic option for children with a multicentric PA or other PAs who are ineligible for or refuse standard therapy or demonstrate persistent, progressive, or recurrent disease following standard therapy.

Keywords: Brain Tumor, Pilocytic Astrocytoma, Multicentric Pilocytic Astrocytoma, Antineoplastons, Phase II Studies

1. Introduction

Pilocytic astrocytoma (PA) is generally a circumscribed, well-differentiated, and slowly growing tumor, classified as World Health Organization (WHO) grade I. PAs exhibit localized cell growth, although they can infiltrate leptomeninges or adjacent brain tissue.

PAs occur most frequently in children and young adults, age 0-19 years [1], accounting for ~10% of cerebral and ~85% of cerebellar tumors. They occur in 15-20% of patients with neurofibromatosis type 1 (NF1), especially in the

optic/chiasmatic region [2]. PAs rarely occur in patients > than 50 years of age [3].

PAs primarily affect the cerebellum but may arise in the optic pathway, hypothalamus, brainstem and spinal cord [4, 5]. Less frequently, they are located in the basal ganglia and cerebral hemispheres. In the pediatric age group, PAs primarily affect the hemispheres of the cerebellum, but also the brain stem and spinal cord. Less frequently, PAs may develop in the neurohypophysis/suprasellar region [6] and pineal gland [8]. Rarely, a pediatric PA may occur as a cerebellopontine angle mass [9, 10].

In adult patients, most PAs are located in the supratentorial region of the brain [11, 12], but can also be located in the cerebellum [13], cervicomedullary region [14] or other parts of the spinal cord [15, 16]. Infrequently, adult PA patients present with a spontaneous intracranial hemorrhage [17].

On gadolinium-enhanced magnetic resonance imaging, (MRI) PAs present as well-demarcated, contrast-enhancing tumors with solid and micro- or macrocytic components [18]. Therefore, a cyst with an enhancing mural nodule is a classic radiological feature of PAs. The solid part usually shows homogeneous contrast enhancement. On non-contrast MRI, PAs appear hypo- or isointense on T1-weighted images and hyperintense on T2-weighted images [19].

Cerebellar and superficial cerebral PAs are surgically treated by gross total or subtotal resection. Deeply situated lesions are resected to the extent possible. Multicentric PAs are treated with some combination of surgical resection, chemotherapy, and extended-field radiotherapy (RT) [20]. Since PAs are generally indolent tumors, overly aggressive therapy is to be avoided [21].

The great majority of PAs show benign clinical behavior and have a good long-term outcome [4, 5, 22]. However, some tumors, despite benign-appearing histology, can be aggressive. In addition to features of anaplasia such as necrosis, increased mitoses and vascular proliferation, which appear in the occasional PA, the pilomyxoid variant pilocytic astrocytoma (PMA) represents a subtype with more invasive growth and an increased risk of recurrences [23, 24]. A worse prognosis is also associated with partial resection, brainstem location, and adult age [4]. PA is usually characterized by distinct clinical features, but occasionally it presents in an older patient, an uncommon location, and/or with multicentric disease [4].

We present a six-year-old white female who came to the Burzynski Clinic (BC) with a newly-diagnosed multicentric PA involving the optic chiasm, hypothalamus, and left hemisphere, was treated with Antineoplastons A10 (Atengenal) and AS2-1 (Astugenal) (ANP therapy), and obtained a complete response (CR).

2. Materials and Methods

ANP research began in 1967, when significant deficiencies were noticed in the peptide content of the serum of patients with cancer compared with healthy persons. Initially ANP were isolated from the blood and later from urine [25]. Subsequent studies of the isolated ANP demonstrated that Antineoplaston A-10 and Antineoplaston AS2-1 were the most active ANPs. The chemical name of Antineoplaston A-10 is 3-phenylacetyl-amino-2,6-piperidinedione. It consists of the cyclic form of L-glutamine connected by a peptide bond to phenylacetyl residue. When given orally, Antineoplaston A10 resists the attack of gastric enzymes. In the small intestine, under alkaline conditions, 30% is digested into phenylacetylglutamine (PG) and phenylacetylisoglutamate (isoPG) in a ratio of approximately 4:1. The mixture of synthetic PG and isoPG in a 4:1 ratio, dissolved in sterile water constitutes Antineoplaston A10 intravenous (IV)

injection. Further metabolism of Antineoplaston A10 results in phenylacetate (PN). Both metabolites PG and PN have anticancer activity. The mixture of PN and PG in a 4:1 ratio, dissolved in sterile water constitutes Antineoplaston AS2-1 IV injection. [26].

In the summer of 1999, a healthy six year-old white female developed difficulty reading. Ophthalmologic examination showed blurring of the right optic disc consistent with optic nerve atrophy. Brain MRI performed elsewhere revealed the presence of a multi-centric tumor involving the optic chiasm, hypothalamus, and left hemisphere. Six enhancing lesions were identified, of which three were target lesions (≥ 5 mm). The child underwent stereotactic biopsy on October 13, 1999 and histologic examination of the microscopic sections revealed pilocytic astrocytoma. The patient was not a candidate for surgery or radiotherapy. She was offered conventional chemotherapy including Vincristine and Carboplatin, but her parents refused and elected to bring her to the Burzynski Clinic (BC) for evaluation and treatment.

On November 11, 1999, this white female, now six years and nine-month-old, was seen at the BC with right-sided hemianopsia, and decreased visual acuity due to the newly-diagnosed, multicentric PA. On physical exam, the patient was alert and orientated. The right optic disc was blurred. Otherwise, her cranial nerves were intact. Deep tendon reflexes were normal bilaterally, with down going toes. On November 15, 1999, baseline brain MRI (see Figure 1) showed multicentric enhancing tumors, of which three were target lesions (≥ 5 mm). The volume of each measurable lesion was determined utilizing their greatest perpendicular diameters. The sum of these measurements was 16.49 cm². The patient was felt to be a good candidate for treatment according to Protocol BT-23, "Antineoplastons A10 and AS2-1 in the treatment of children with optic pathway glioma", a single arm, two-stage, phase II study [27].

3. Results

The patient began ANP therapy on November 11, 1999. It was delivered via a subclavian catheter and a programmable infusion pump. The dose of ANP therapy was increased until the maximum tolerated dose was achieved. The maximum tolerated dosage of Antineoplaston A10 was 15.8 g/kg/d while the maximum tolerated dosage of Antineoplaston AS2-1 was 0.52 g/kg/d. Intravenous (IV) ANP therapy was permanently discontinued on August 22, 2000 due to an objective response (OR), but the patient was continued on oral ANP therapy until April 14, 2003. Oral ANP Therapy was resumed on 4/20/2004 due to questionable enhancement on a follow-up brain MRI. This was stopped on 3/25/2006.

Response to ANP therapy was measured by serial brain MRIs. The response criteria were as follows: a CR indicated complete disappearance of all enhancing tumor while a partial response (PR) indicated a 50% or greater reduction in total enhancing tumor volume. CR and PR required a confirmatory brain MRI performed at least four weeks after the initial finding. PD indicated a 25% or greater increase in

enhancing tumor volume, or new enhancing disease, while stable disease (SD) did not meet the criteria for PR or PD [28]. All brain MRIs were reviewed by a prominent outside radiologist.

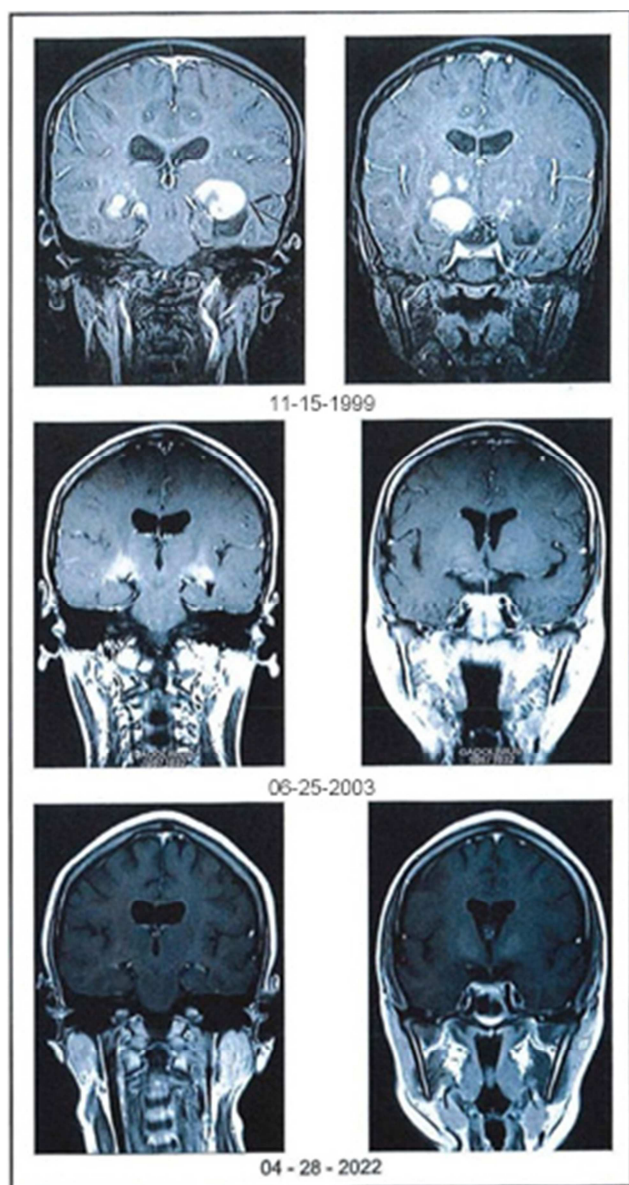


Figure 1. Coronal MRI images of the brain on 11-15-1999 (baseline) showing multicentric pilocytic astrocytoma – three target lesions (> 5mm diameter) were identified, one to the right of midline (see arrow) and two to the left of midline; on 06-25-2003 showing a CR; and on 04-28-2022 showing long-term continuation of the CR. Axial images confirmed these findings. CR=complete response; MRI=magnetic resonance imaging.

On April 12, 2000, after 5 months of ANP therapy, follow-up brain MRI revealed the sum of the volumes of the three target lesions to be 4.32 cm² a decrease of 73.8% from baseline, indicating a PR had been achieved. On June 25, 2003, follow-up brain MRI revealed no remaining enhancing disease indicating a CR had been achieved (Figure 1). Repeat brain MRI on April 28, 2022, demonstrated the persistent absence of disease (Figure 1). The patient was maintaining an excellent quality of life (Figure 2).



Figure 2. Post-treatment photograph of the patient.

The most recent follow-up brain MRI was on April 28, 2022. At that time, the patient was 29 years of age and, since the start of ANP therapy, had survived over 22 years. There had been no evidence of tumor recurrence. There had been no long-term disability related to ANP therapy. The patient had not received any additional anti-tumor therapy since ANP therapy was discontinued. The patient has consented to publication of the radiographs and photograph presented herein.

The patient experienced four grade 1 and one grade 2 adverse events (AEs) thought to be related to ANP therapy and had a full recovery from each AE.

4. Discussion

Multicentric disease occurs because of the unique propensity of glioma cells to invade normal brain or spinal cord and migrate long distances [29]. There is no standard therapy for this condition, but usually combines appropriate surgery, RT, and conventional chemotherapy.

Previously, we reported on ANP therapy in children with recurrent and progressive multicentric glioma and described favorable outcomes for children treated with ANP therapy when compared to children treated with radiation therapy and chemotherapy. We suggested that confirmation of these results through further studies could introduce a new therapeutic option for patients with multicentric gliomas [30].

Subsequently, we reported on multicentric disease in children treated in Phase II studies under the Burzynski Research Institute (BRI) IND # 43,742 [31]. We reported a 17.5% OR rate (i.e., 10 children) in 57 children receiving ANP therapy for leptomeningeal, disseminated, and/or multicentric disease (LDM). Two- and five-year overall survival (OS) in the 57 children were 28% while 10- and 15-year OS were 26%. Most of the responding children were diagnosed with a low-grade glioma. We were unable to find comparable series in the published literature but suggested that this data indicated a possible role for ANP therapy in the treatment of children with LDM.

Epigenetic mechanisms involving the tumor suppressor genes TP53, p21, NF1, and the RAS oncogene pathway (GR-RTK-RAS) cause glial cells to become invasive and resistant to conventional therapies. The natural ability of glial cells to migrate extensively during development may explain their

ability to form multicentric lesions. All these factors may therefore affect the occurrence of multicentric disease. The natural history of multicentric disease is responsible for the failure of conventional approaches including appropriate surgery, RT, and chemotherapy. The cells in multicentric disease appear to activate a migratory phenotype and appear to temporarily lower their proliferation rate, rendering them relatively resistant to RT and conventional chemotherapy [32]. Therefore, therapies exploring epigenetic mechanisms may be more efficacious.

ANP's mechanism of action differs from that of radiation therapy (RT) or cytotoxic chemotherapy. Growth of normal cells is controlled by cell cycle progression genes (oncogenes) and by cell cycle arrest genes (tumor suppressor genes). In cancer, alteration of these control genes in malignant cells favors aggressive cell proliferation. Evidence suggests that ANP affects 112 genes in the tumor genome and functions as "molecular switches" which "turn on" tumor-suppressor genes and "turn off" oncogenes. [25, 26] Hence, the antineoplastic action of ANP therapy in DIPG involves restoration of cell cycle control, induction of programmed cell death, and interference with cancer cell metabolism and nuclear transport.

5. Conclusions

We have presented here the case of a six year and nine-month-old female with a newly diagnosed multicentric PA who obtained a cure with ANP therapy. This therapy is an attractive option for patients with a multicentric PA or other PAs who are ineligible for or refuse standard therapy or demonstrate persistent, progressive, or recurrent disease following standard therapy. Multiple Phase II clinical studies of ANP therapy in a variety of low-and high-grade brain tumors under the Burzynski Research Institute's (BRI's) IND # 43,742 have now been completed and numerous articles have been published [33-74]. Based on our previous studies of multicentric disease [30, 31], a phase III clinical study will be developed.

Acknowledgements

The authors express their appreciation to Carolyn Powers for preparation of the manuscript and to Ramiro Rivera, Mohamed Khan, Jennifer Pineda and Adam Golunski for their involvement.

References

- [1] Ostrom QT, Gittleman H, Liao P, Rouse C, Chen Y, Dowling J, Wolinsky Y, Kruchko C, Barnholtz-Sloan J. (2014) CBTRUS statistical report: primary brain and central nervous system tumors diagnosed in the United States in 2007-2011. *Neuro Oncol*, 16 Suppl 4, iv1-63.
- [2] Listernick R, Ferner RE, Liu GT, Gutmann DH. (2013) Optic pathway gliomas in neurofibromatosis-1: controversies and recommendations. *Ann Neurol*, 61, 189-198.
- [3] Burkhardt K, Heuberger F, Delavelle J. Pilocytic astrocytoma in the elderly. (2007) *Clin Neuropathol*, 26, 306-310.
- [4] Cyrine S, Sonia Z, Mounir T, Badderedine S, Kalthoum T, Hedi K, Moncef M. (2013) Pilocytic astrocytoma: a retrospective study of 32 cases. *Clin Neurol Neurosurg*, 115, 1220-1225.
- [5] Daszkiewicz P, Maryniak A, Roszkowski M, Barszcz S. (2009) Long-term functional outcome of surgical treatment of juvenile pilocytic astrocytoma of the cerebellum in children. *Childs Nerv Syst*, 25, 855-860.
- [6] Reis A, Kuzeyle K, Cobanoglu U, Cakir E, Usul H, Sari A. (2003) Pilocytic astrocytoma of neurohypophysis. *Neuropathology*, 23, 214-218.
- [7] Dodgshun AJ, Maixner WJ, Hansford JR, Sullivan MJ. (2016) Low rates of recurrence and slow progression of pediatric pilocytic astrocytoma after gross-total resection: justification for reducing surveillance imaging. *J Neurosurg Pediatr*, 17, 569-572.
- [8] Arantes M, Vaz AR, Honavar M, Resende M, Pereira JR. (2009) Pilocytic astrocytoma arising from the pineal gland. *J Neuroradiol*, 36, 177-178.
- [9] Mirone G, Schiabello L, Chibbaro S, Bouazza S, George B. (2009) Pediatric primary pilocytic astrocytoma of the cerebellopontine angle: a case report. *Childs Nerv Syst*, 25, 247-251.
- [10] Takada Y, Ohno K, Tamaki M, Hirakawa K. (1999) Cerebellopontine angle pilocytic astrocytoma mimicking acoustic schwannoma. *Neuroradiology*, 41, 949-950.
- [11] Bell D, Chitnavis BP, Al-Sarraj S, Connor S, Sharr MM, Gullan RW. (2004) Pilocytic astrocytoma of the adult--clinical features, radiological features and management. *Br J Neurosurg*, 18, 613-616.
- [12] Brown PD, Anderson SK, Carrero XW, O'Neill BP, Giannini C, Galanis E, Shah SA, Abrams RA, Curran WJ Jr, Buckner JC, Shaw EG. (2015) Adult patients with supratentorial pilocytic astrocytoma: long-term follow-up of prospective multicenter clinical trial NCCTG-867251 (Alliance). *Neurooncol Pract*, 2, 199-204.
- [13] Wade A, Hayhurst C, Amato-Watkins A, Lammie A, Leach P. (2013) Cerebellar pilocytic astrocytoma in adults: a management paradigm for a rare tumour. *Acta Neurochir (Wien)*, 155, 1431-1435.
- [14] Zhao Y, Feng L, Wei Q, Gao L. (2015) Adult cervicomedullary pilocytic astrocytoma: A case report. *Experimental and therapeutic medicine*, 10, 2221-2223.
- [15] Pasarikovski CR, Allevato PA, Hammond R, Elashaal AA. (2015) Pilocytic astrocytoma of the lower thoracic spine in an adult patient. *Acta Neurochir (Wien)*, 157, 1179-1181.
- [16] Saad A, Tuli S, Ali EN, Houtchens M, Delalle I, Kesari S. (2008) Pilocytic astrocytoma of the spinal cord in an adult. *J Neurooncol*, 88, 189-191.
- [17] Li HM, Hsu SS, Wang JS, Weng MJ, Fu JH, Chen CK, Lai PH. (2008) Cerebral pilocytic astrocytoma with spontaneous intracranial hemorrhage in adults. *J Chin Med Assoc*, 71, 587-593.

- [18] Xia J, Yin B, Liu L, Lu Y, Geng D, Tian W. (2015) Imaging Features of Pilocytic Astrocytoma in Cerebral Ventricles. *Clin Neuroradiol*, 26 (3), 341-346.
- [19] Lee YY, Van Tassel P, Bruner JM, Moser RP, Share JC. (1989) Juvenile pilocytic astrocytomas: CT and MR characteristics. *AJR Am J Roentgenol*, 152, 1263-1270.
- [20] Bian SX, McAleer MF, Vats TS, Mahajan A, Grosshans DR. (2013) Pilocytic astrocytoma with leptomeningeal dissemination. *Childs Nerv Syst*, 29, 441-450.
- [21] Reis GF, Tihan T. Therapeutic targets in pilocytic astrocytoma based on genetic analysis. (2015) *Semin Pediatr Neurol*, 22, 23-27.
- [22] Malik A, Deb P, Sharma MC, Sarkar C. Neuropathological spectrum of pilocytic astrocytoma: an Indian series of 120 cases. (2006) *Pathol Oncol Res*, 12, 164-171.
- [23] Komotar RJ, Mocco J, Carson BS, Sughrue ME, Zacharia BE, Sisti AC, Canoll PD, Khandji AG, Tihan T, Burger PC, Bruce JN. (2004) Pilomyxoid astrocytoma: a review. *MedGenMed*, 6, 42.
- [24] Komotar RJ, Mocco J, Jones JE, Zacharia BE, Tihan T, Feldstein NA, Anderson RC. (2005) Pilomyxoid astrocytoma: diagnosis, prognosis, and management. *Neurosurg Focus*, 18, E7.
- [25] Burzynski SR. (1976) Antineoplastons: Biochemical defense against cancer. *Physiol Chem Phys*, 8, 275-279.
- [26] Burzynski SR. (1986) Synthetic antineoplastons and analogs: Drugs of the future, 11, 679-688.
- [27] Burzynski SR, Janicki TJ, Burzynski GS. (2017) Antineoplastons A10 and AS2-1 in the treatment of children with optic pathway glioma. Final report (Protocol BT-23). *Cancer Clin Oncol*, 6 (1), 25-35.
- [28] Wen PK, Macdonald DR, Reardon DA, et al. (2010) Updated response criteria for high-grade gliomas: Response Assessment in Neuro-Oncology (RANO) working group. *J Clin Oncol*, 28 (11), 1963-1972.
- [29] Claes A, Idema AJ, Wesseling P. (2007). Diffuse glioma growth: a guerilla war. *Acta Neuropathologica*, 114, 443-458. doi:10.1007/s00401-007-0293-7.
- [30] Burzynski SR, Weaver RA, Lewy RI, Janicki TJ, Jurida GF, et al. (2004). Phase II study of Antineoplaston A10 and AS2-1 in children with recurrent and progressive multicentric glioma: A preliminary report. *Drugs in R & D*, 5, 315-326. doi:10.2165/0012.
- [31] Burzynski S, Janicki TJ, Burzynski GS. (2016) Primary CNS tumors and leptomeningeal, disseminated, and/or multicentric disease in children treated in phase II studies with antineoplastons A10 and AS2-1. *Cancer Clin Oncol*, 5 (2), 38-48. doi:10.5539/cco.v5n2938.
- [32] Giese A, Bjerkvig A, Berens ME, et al. (2003) Cost of migration: Invasion of malignant gliomas and implications for treatment. *J Clin Oncol*, 21, 1624-36.
- [33] Burzynski SR, Janicki T, Burzynski G. (2015) A phase II study of Antineoplastons A10 and AS in adult patients with primary brain tumors: Final report (Protocol BT-09). *J Cancer Ther*, 6, 1063-1074. doi.org/10.4236/jct.2015.612116.
- [34] Burzynski SR, Patil S. (2014) The effect of Antineoplastons A10 and AS2-1 and metabolites of sodium phenylbutyrate on gene expression in glioblastoma multiforme. *J Cancer Ther*, 5, 929-945.
- [35] Hawkins MG, Friedman MA. (1992) National Cancer Institute's evaluation of unconventional cancer treatments. *J Natl Cancer Inst*, 84, 1699-1702.
- [36] Burzynski SR, Janicki T, Burzynski G. (2015) Comprehensive genomic profiling of recurrent classic glioblastoma in a patient surviving eleven years following antineoplaston therapy. *Cancer Clin Oncol*, 4 (2), 41-52.
- [37] Burzynski SR, Conde AB, Peters A, Saling B, Ellithorpe R, Daugherty JP, Nacht CH. (1999) A Retrospective Study of Antineoplastons A10 and AS2-1 in Primary Brain Tumors. *Clin Drug Invest*, 18, 1-10.
- [38] Burzynski SR, Weaver RA, Bestak M, Lewy RI, Janicki TJ, Jurida GF, Paszkowiak JK, Szymkowski BG, Khan MI. (2003) Phase II study of Antineoplastons A10 and AS2-1 (ANP) in children with recurrent and progressive multicentric glioma: A preliminary report. *Neuro Oncol*, 5, 358.
- [39] Burzynski SR, Lewy RI, Weaver R, Janicki T, Jurida G, Khan M, Larisma CB, Paszkowiak J, Szymkowski B. (2004) Long-term survival and complete response of a patient with recurrent diffuse intrinsic brain stem glioblastoma multiforme. *Integ Cancer Ther*, 3, 257-261. doi: 10.1177/1534735404267748.
- [40] Burzynski SR, Weaver R, Lewy R, Janicki T, Jurida G, Szymkowski B, Khan M, Bestak M. (2004) Phase II study of antineoplaston A10 and AS2-1 in children with recurrent and progressive multicentric glioma: A preliminary report. *Drugs R&D*, 5 (6), 315-326.
- [41] Burzynski SR, Weaver R, Bestak M, Janicki T, Jurida G., Szymkowski B, Khan M, Dolgoplov V. (2004) Phase II studies of antineoplastons A10 and AS2-1 (ANP) in children with atypical teratoid/rhabdoid tumors (AT/RT) of the central nervous system: A preliminary report. *Neuro Oncol*, 6, 427.
- [42] Burzynski SR, Weaver R, Bestak M, Janicki T, Szymkowski B, Jurida G, Khan M, Dolgoplov V. (2004) Treatment of primitive neuroectodermal tumors (PNET) with antineoplastons A10 and AS2-1 (ANP): Preliminary results of phase II studies. *Neuro Oncol*, 6, 428.
- [43] Burzynski SR, Weaver RA, Janicki T, Szymkowski B, Jurida G, Khan M, Dolgoplov V. (2005) Long-term survival of high-risk pediatric patients with primitive neuroectodermal tumors treated with Antineoplastons A10 and AS2-1. *Integ Cancer Ther*, 4 (2), 168-177. doi: 10.1177/1534735404267748.
- [44] Burzynski SR. (2006) Targeted Therapy for Brain Tumors. In: Yang AV, editor. *Brain Cancer Therapy and Surgical Interventions*. Nova Science Publishers, Inc, New York.
- [45] Burzynski SR, Janicki TJ, Weaver RA, Burzynski B. (2006) Targeted therapy with Antineoplastons A10 and AS2-1 of high grade, recurrent, and progressive brainstem glioma. *Integ Cancer Ther*, 5 (1), 40-47. doi: 10.1177/1534735405285380.
- [46] Burzynski SR. (2006) Treatments for astrocytic tumors in children: Current and emerging strategies. *Ped Drugs*, 8, 167-168. doi.org/10.2165/00148581-200608030-00003.

- [47] Burzynski SR. (2007) Recent clinical trials in diffuse intrinsic brainstem glioma. *Cancer Ther*, 5, 379- 390.
- [48] Burzynski S, Janicki T, Burzynski G, Marszalek A. (2014) Long-term survival (>13 years) in a child with recurrent diffuse pontine gliosarcoma: A case report. *J Ped Hematol Oncol*, 36: 433-439. doi: 10.1097/MPH.000000000000020.
- [49] Burzynski SR, Janicki TJ, Burzynski GS, Marszalek A. (2014) A phase II study of antineoplastons A10 and AS2-1 in children with high-grade glioma: Final report (Protocol BT-06) and review of recent trials. *J Cancer Ther*, 5, 565-577. doi.org/10.4236/jct.2014.56065.
- [50] Burzynski SR, Janicki TJ, Burzynski GS. (2014) A phase II study of antineoplastons A10 and AS2-1 in adult patients with recurrent glioblastoma multiforme: Final report (Protocol BT-21). *J Cancer Ther*, 5, 946-956. doi.org/10.4236/jct.2014.510100.
- [51] Burzynski SR, Burzynski GS, Janicki TJ. (2014) Recurrent glioblastoma multiforme: A strategy for long-term survival. *J Cancer Ther*, 5, 957-976. doi.org/10.4236/jct.2014.510101.
- [52] Burzynski SR, Janicki TJ, Burzynski GS, Marszalek A, Brookman S. (2014) A phase II study of antineoplastons A10 and AS2-1 in children with recurrent, refractory or progressive primary brain tumors: Final report (Protocol BT-22). *J Cancer Ther*, 5, 977-988. doi.org/10.4236/jct.2014.510102.
- [53] Burzynski SR, Janicki TJ, Burzynski GS, Brookman S. (2014) Preliminary findings on the use of targeted therapy with pazopanib and other agents in combination with sodium phenylbutyrate in the treatment of glioblastoma multiforme. *J Cancer Ther*, 5, 1423-1437.
- [54] Burzynski GS, Janicki TJ, Marszalek A. (2014) Long-term survival (>20 years) of a child with brainstem glioma treated with antineoplastons A10 and AS2-1: A case report. *Neuro Oncol*, 11, 16.
- [55] Burzynski SR, Janicki TJ, Burzynski GS, Marszalek. (2014) The response and survival of children with recurrent diffuse intrinsic pontine glioma based on phase II study of antineoplastons A10 and AS2-1 in patients with brainstem glioma. *Childs Nerv Syst*, 30; 2051-2061. doi.org/10.1007/s00381- 014-2401-z.
- [56] Burzynski SR, Burzynski G, Janicki J, Marszalek A. (2015) Complete response and Long-term survival (>20 years) of a child with tectal glioma: A case report. *Pediatr Neurosurg*, 50, 99-103. doi: 10.1159/000369907.
- [57] Burzynski SR, Janicki TJ, Burzynski G. (2015) A phase II study of Antineoplastons A10 and AS2-1 injections in adult patients with recurrent anaplastic astrocytoma: Final report (Protocol BT-15). *Cancer Clin Oncol*, 442, 13-23.
- [58] Burzynski SR, Janicki TJ, Burzynski GS, Marszalek A. (2015) A Phase II Study of Antineoplastons A10 and AS2-1 in adult patients with newly-diagnosed anaplastic astrocytoma: Final report (Protocol BT-08). *Cancer Clin Oncol*, 4, 28-38.
- [59] Burzynski SR, Burzynski GS, Marszalek A, Janicki J, Martinez-Canca J. (2015) Long-term survival (over 20 years), complete response and normal childhood development in medulloblastoma treated with Antineoplastons A10 and AS2-1. *J Neurol Stroke*, 2 (3), 00054.
- [60] Burzynski SR, Burzynski GS, Marszalek A, Janicki TJ, Martinez-Canca JF. (2015) Long-term survival over 21 years and pathologically confirmed complete response in pediatric anaplastic astrocytoma: A case report. *J Neurol Stroke*, 2 (6), 00072.
- [61] Burzynski SR, Burzynski GS, Brookman S. (2015) A case of sustained objective response of recurrent/progressive diffuse intrinsic pontine glioma with phenylbutyrate and targeted agents. *J Cancer Ther*, 6, 40-44. doi: 10.4236/jct.2015.61006.
- [62] Burzynski SR, Janicki T, Burzynski G, Marszalek A. (2015) A phase II study of antineoplastons A10 and AS2-1 in patients with brainstem gliomas: The report on non-diffuse intrinsic pontine glioma (Protocol BT-11). *J Cancer Ther*, 6, 334-344. doi: 10.4236/jct.2017.82015.
- [63] Burzynski SR, Janicki T, Burzynski G. (2015) A phase II study of Antineoplastons A10 and AS2-1 in adult patients with primary brain tumors: Final report (Protocol BT-09), *J Cancer Ther*, 6, 1063-1074. doi.org/10.4236/jct.2015.612116.
- [64] Burzynski SR, Janicki TJ, Burzynski GS. (2016) Primary CNS tumors and leptomeningeal, disseminated and/or multicentric disease in children treated in Phase II studies with Antineoplastons A10 and AS2-1. *Cancer Clin Oncol*, 5 (2), 38-48.
- [65] Burzynski SR, Janicki TJ, Burzynski GS. (2016) A phase II study of antineoplastons A10 and AS2-1 in children with low-grade astrocytomas: Final report (Protocol BT-13). *J Cancer Ther*, 7 (12): 837-850.
- [66] Burzynski SR, Janicki TJ, Burzynski GS, Marszalek A. (2017) A phase II study of Antineoplastons A10 and AS2-1 in children with brain tumors: Final report (Protocol BT-10). *J Cancer Ther*, 8, 173-187.
- [67] Burzynski SR, Janicki T, Beenken, S. (2019) Treatment of recurrent glioblastoma multiforme (rGBM) with Antineoplastron AS2-1 in combination with targeted therapy. *Cancer Clin Oncol*, 8, 1-15.
- [68] Burzynski, SR, Janicki, T, Burzynski, GS, Beenken, S. (2021) Long-term survival (27.7 years) following IV Antineoplastron Therapy (ANP) in a 36-year-old-female with a progressive diffuse intrinsic pontine glioma (DIPG). *Int J Radiol Imaging Technol*, 7, 073-078. doi: 10.23937/2572-3235.1510073.
- [69] Burzynski, SR, Burzynski, GS, Janicki, T, Beenken S. (2021) Long-term survival (23 years) in a 26-year-old male after Antineoplastron therapy for a progressive, diffuse intrinsic pontine glioma: A case report. *Int J Brain Disord Treat*, 6, 038-044. doi.org/10.23937/2469-5866/
- [70] Burzynski, SR, Janicki T, Burzynski GS, Beenken S. (2021) Resolution of clinical signs, a complete response, and long-term survival (>23 Years) in a 3 and ½ month female with a newly diagnosed diffuse intrinsic pontine glioma treated with antineoplastons. *Biomed Res Clin Prac*, 6: doi: 10.15761/BRCP.1000220.
- [71] Burzynski, SR, Janicki T, Burzynski GS, Beenken S. (2021) Diffuse intrinsic pontine glioma in an 11-year-old female treated with antineoplastons: Complete response and > 25-year survival. *Pediatr Neonatal Med*, 1 (2), 1-5.
- [72] Burzynski SR, Janicki T, Burzynski GS, Beenken S. (2022) A 25-year-old female with diffuse intrinsic pontine glioma surviving for more than nine years following treatment with antineoplastons. *Int J Clin Oncol Cancer Res*, 7, 1-7.

- [73] Burzynski SR, Burzynski GS, Janicki T, Beenken S. (2022) Twenty-two-year survival in a 15-year-old female with a recurrent posterior fossa ependymoma treated with antineoplastons. *Oncol Clin Res*, 3 (1), 99-105.
- [74] Burzynski S, Burzynski G, Janicki T, Beenken, S. (2022) Recurrent and progressive ganglioglioma in an 11-year-old male treated with antineoplastons: Partial response with more than nine years and nine months survival and complete resolution of clinical symptoms/signs. *Biomed Res. J*, In Press.