



The Role of Peptide Immunotherapy in the Treatment of Cervical Dysplasia: Clinical Cases

Olga Bulavenko¹, Tetiana Lunko², Oleksii Tatskyy³, Tetiana Fomina⁴, Maria Pikul⁵,
Oleksandr Zdanevych⁶, Mykhailo Kazarnovskyy⁷, Victor Zadorozhnyy⁷, Svitlana Turbanist⁸,
Svitlana Pysmenna⁹, Olena Yamkova-Bodnaruk¹⁰, Liudmyla Lytvynchuk¹¹

¹Department of Obstetrics and Gynecology, No. 2 of M. I. Pyrogov Vinnytskyy National Medical University, Vinnytsia, Ukraine

²Department of Obstetrics and Gynecology, Odeskyy National Medical University, Odesa, Ukraine

³Department of Research and Development, International Biotherapy Institute, Kyiv, Ukraine

⁴Department of Gynecology, Women's Health Center "Remedivin", Vinnytsia, Ukraine

⁵Department of Gynecology, Cherkasy Regional Clinical Hospital, Cherkasy, Ukraine

⁶Department of Oncogynecology, Cherkasy Regional Oncology Dispensary, Cherkasy, Ukraine

⁷Department of Oncogynecology, Odesa Regional Clinical Antitumor Center, Odesa, Ukraine

⁸Department of Gynecology, Private Gynecological Clinic "Isida", Kyiv, Ukraine

⁹Department of Gynecology, Women's Consultation No. 2, Cherkasy, Ukraine

¹⁰Department of Gynecology, Medical Center "Innomed", Vinnytsia, Ukraine

¹¹Department of Oncogynecology, Podilskyy Regional Oncology Center, Vinnytsia, Ukraine

Email address:

taf-kiiev@ukr.net (Oleksii Tatskyy)

To cite this article:

Olga Bulavenko, Tetiana Lunko, Oleksii Tatskyy, Tetiana Fomina, Maria Pikul, Oleksandr Zdanevych, Mykhailo Kazarnovskyy, Victor Zadorozhnyy, Svitlana Turbanist, Svitlana Pysmenna, Olena Yamkova-Bodnaruk, Liudmyla Lytvynchuk. The Role of Peptide Immunotherapy in the Treatment of Cervical Dysplasia: Clinical Cases. *International Journal of Clinical Oncology and Cancer Research*. Vol. 8, No. 2, 2023, pp. 32-38. doi: 10.11648/j.ijccocr.20230802.13

Received: April 12, 2023; **Accepted:** May 15, 2023; **Published:** May 25, 2023

Abstract: *Introduction.* Since one of the main factors determining the pathogenic effect of HPV infection is local immunodeficiency, a number of authors suggest using various cytokines and immunomodulators. Recently, peptide-based agents have been increasingly used in routine clinical practice. *Objective.* To study the effect of peptide immunocorrection on molecular and cellular factors affecting the course of grade II cervical dysplasia (CIN2) as a precancerous process and to evaluate the effectiveness of the proposed regimen. *Materials and methods.* The study included 2 groups of patients aged 28 to 44 years who were colposcopically and cytologically diagnosed with grade 2 cervical dysplasia. Clinical monitoring, determination of HPV by PCR, immunohistochemical studies of biomarkers of inflammation and proliferation, as well as counting of T-lymphocytes in cervical mucus preparations were performed before treatment, after treatment, after 6 weeks and after 3 months. *Results.* During the study of the expression level of pro-oncogenic interleukin IL-8 and anti-oncogenic IL-12, it was established that in both observation groups after the immunotherapy, a tendency to decrease the pro-oncogenic potential of cervical mucus was noted. Analysis of the level of expression of the cell proliferation marker Ki-67 in the clinical monitoring groups showed that the proposed therapy schemes reduced the proliferative potential of the cervical epithelium. The number of active cytotoxic lymphocytes in the cervical mucus in both observation groups predictably increased after the use of local immunotherapy. The study showed that immunotherapy of cervical dysplasia with the use of peptides demonstrated significantly better clinical results compared to the reference group. *Conclusion.* Taking into account the obtained research results and the given clinical cases, peptide immunocorrection can be reasonably recommended as an immunological component in the treatment of cervical dysplasia (ASCUS and LSIL).

Keywords: Cervical Dysplasia, Cervical Cancer, Immunocorrection, Peptides, Effectiveness

1. Introduction

Dysplasia of the cervix (cervical intraepithelial neoplasia - CIN) is a precancerous lesion in the epithelium of the cervix, which is a violation of the process of transformation of cylindrical epithelium into squamous [1, 2]. In dysplasia of the first degree (CIN 1), slight changes occur in the structure of the cells of the basal layer, which affect no more than a third of the epithelium layer. If half of the epithelial layer is affected, namely its lower and middle parts, it is possible to diagnose moderate dysplasia, CIN 2. Severe dysplasia CIN 3 is characterized by changes in all layers of the epithelium, which is expressed in the appearance of pathological mitoses and hyperchromic cell nuclei [3, 4].

The most common cause of dysplasia and, as a result, cervical carcinoma, is the human papillomavirus (HPV), its pro-oncogenic type 16 is responsible for 50% of cervical cancers. HPV 18, 31, 33, 35, 39, 45, 51, 52, 56, 58, 59, 66, and 68 are other oncogenic types of HPV. HPV is a common sexually transmitted infection. Persistent infection is the root cause of dysplasia, which, if left untreated, can lead to cancer. The process is usually slow and lasts several years [5].

To date, the treatment of HPV-associated dysplastic lesions of the cervix includes two basic approaches. The first of them is aimed at the local destruction of the pathologically changed epithelium, and the basis of the second is the inhibition of HPV infection [5, 6]. Each of these approaches has numerous methods in its arsenal, the combination of which is determined individually depending on many factors.

The local destructive effect on the center of the pathologically changed epithelium traditionally remains a justified approach to the treatment of cervical dysplasia. Destructive methods have evolved over time from more radical ones, which are considered conization of the cervix and electrocoagulation of areas of altered epithelium, to less traumatic ones (use of cryodestruction, radiosurgery, CO₂-laser vaporization, and others) [7, 8].

Meanwhile, more and more facts are accumulating that excessive use of surgical treatment methods in young women leads to impaired reproductive function, worsens the course of pregnancy and childbirth. It should be noted that local destruction of the cervix does not eliminate the main etiological factor of cervical dysplasia (CD) and cervical cancer (CC), therefore, in 28 - 30% of cases, a recurrence of the disease occurs within 2-3 years. But despite constant searches for the possibility of an etiological influence on HPV infection, there is currently no effective way to eliminate the virus [6-8].

It should also be noted that various molecular and cellular factors influence the clinical course and prognosis of CD and CC. Ki-67 is a proliferation marker that is expressed only in active phases of the cell cycle (phases G₁, S, G₂ and M). Since HPV infection leads to increased proliferation of epithelial cells in infected tissue, increased expression of Ki-67 may be an indicator of papillomavirus infection. Ki-67 can be not only an informative marker of proliferation in dysplastic lesions, but also has a prognostic value [9].

One of the key roles in the progression or regression of precancerous changes is played by interleukins: pro-inflammatory ones such as IL-1, IL-6, IL-8, IL-17 stimulate malignant transformation, and anti-inflammatory IL-2, IL-12, IL-21, IL-37 prevent it [10-12]. Cytotoxic killer T-lymphocytes (CD8+) and T-helpers (CD4+) are distinguished among the cellular regulators of the chronic infectious and inflammatory process. Studies have shown an equal proportion of CD4+ and CD8+ cells in the stroma of preneoplastic lesions and a low density of CD4+ cells in the epithelium of preneoplastic lesions compared with normal tissues. In addition, it is reported that in CC, a large number of CD8+ is associated with the absence of metastases [13, 14].

Since one of the main factors determining the pathogenic effect of HPV infection is local immunodeficiency, a number of authors suggest using various cytokines and immunomodulators [15-17]. Recently, peptide-based agents have been increasingly used in routine clinical practice [18-22]. One of these drugs is the peptide immunocorrector Arecur, which is used in gynecological practice in the form of vaginal suppositories and has proven its effectiveness in the treatment of endocervicitis, grade 1-2 dysplasia, and endometrioma [23, 24].

2. Objective

To study the effect of peptide immunocorrection on molecular and cellular factors affecting the course of grade II cervical dysplasia (CIN2) as a precancerous process and to evaluate the effectiveness of the proposed technique.

3. Materials and Methods

The study included 2 groups of patients aged 28 to 44 who were colposcopically and cytologically diagnosed with grade 2 cervical dysplasia (CIN2): group A included 59 women who were prescribed vaginal suppositories as immunotherapy - a preparation of natural immune peptides (Arecur) 1 suppository of 2.0 g once a day in the evening for 20 days; in group B - 44 patients who received vaginal suppositories with interferon, 500,000 IU, once a day for 20 days. Clinical monitoring, determination of HPV by PCR, immunohistochemical studies of biomarkers of inflammation and proliferation, as well as counting of T-lymphocytes in cervical mucus preparations were carried out before treatment, after treatment, after 6 weeks and after 3 months (according to the protocol No. 236 of the Ministry of Health of Ukraine "Cervical dysplasia and cervical cancer").

In the course of the study, the level of IL-8 and IL-12 in the cervical mucus of patients was determined using the immunoenzymatic method, using a kit "Orgenium" (Finland), on the analyzer "Awareness Technology Stat Fax 303 Plus Microstrip Reader" (USA). The expression of Ki-67 was studied by the immunocytochemical method using appropriate monoclonal antibodies (McAt), and the Lab Vision™ UltraVision™ Quanto Detection System was used

to detect the ICH reaction. To check the specificity of the McAt interaction and, thus, to obtain reliable results during the research, control reactions were set. Analysis of the results of the ICH reaction was performed by counting immunopositive cells (brown staining of the cytoplasm and/or nuclei) using a PrimoStar light microscope (Zeiss, Germany) at a magnification of $\times 100$ –400. The H-Score method according to the formula was used to quantitatively assess the expression of the investigated ICH markers:

$$S = N_0 (\%) + 3 \times N_1 (\%) + 2 \times N_2 (\%) + 1 \times N_3 (\%),$$

where S is the "H-Score", N_0 is the number (%) of cells with no marker expression, N_1 , N_2 and N_3 are the number (%) of cells with low, medium and high expression of the markers, respectively. The final result of the calculation was expressed in points, for which quantitative indicators in percentages were converted into points. Based on the obtained data, the expression level was considered low (1–100 points), medium (101–200 points) or high (201–300 points). Cytotoxic T-lymphocytes were counted using an indirect immunoperoxidase reaction with monoclonal antibodies to

CD8+ (Thermo Scientific, USA). Visualization of the reaction was performed using the UltraVision LP Detection System HRP Polymer & DAB Plus Chromogen kit (Thermo Scientific, USA). The number of CD8 positive cells was counted on $1 \times 10^{-6} \text{ m}^2$ of tissue area. All studies were conducted in accordance with the Declaration of Helsinki.

Statistical processing of the results was carried out using Excel (MS Office 2010) and Origin 8.1 (OriginLab, USA) programs using the t-test for independent samples of data that corresponded to a normal distribution. Results are presented as arithmetic mean with standard deviation (\pm SD), $p \leq 0.05$ was taken as the critical level of reliability during the testing of statistical hypotheses.

4. Results

During the study of the expression level of pro-oncogenic interleukin IL-8 and anti-oncogenic IL-12, it was established that in both observation groups, after the immunotherapy, there was a tendency to decrease the pro-oncogenic potential of cervical mucus (Tables 1, 2).

Table 1. Expression level of the pro-oncogenic cytokine IL-8 (pg/ml) of cervical mucus in observation groups.

Group/Date	Before treatment	After treatment	In 6 weeks	In 3 months
A (n = 59)	113,20 \pm 4,01*	74,80 \pm 1,09*	77,14 \pm 1,12*	81,44 \pm 3,11*
B (n = 44)	97,27 \pm 3,04	67,02 \pm 3,44	79,11 \pm 1,05	91,21 \pm 1,77

* - Note: compared to the reference group, $p \leq 0.05$.

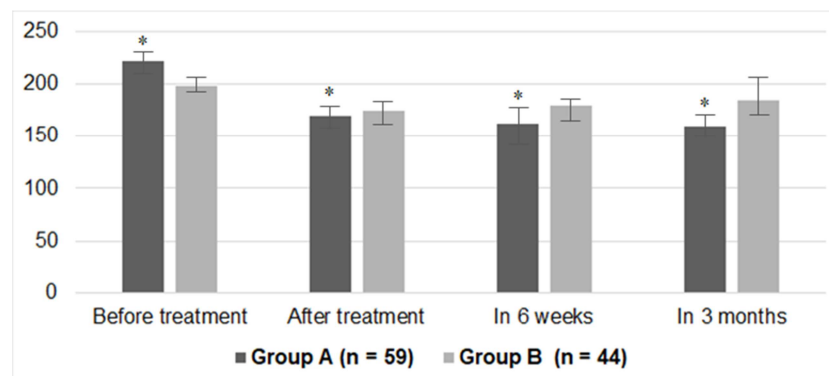
Table 2. Expression level of the anti-oncogenic cytokine IL-12 (pg/ml) of cervical mucus in observation groups.

Group/Date	Before treatment	After treatment	In 6 weeks	In 3 months
A (n = 59)	74,96 \pm 2,44*	99,80 \pm 2,12*	112,66 \pm 2,09*	109,80 \pm 2,04*
B (n = 44)	87,07 \pm 1,08	114,80 \pm 2,12	109,22 \pm 3,04	94,44 \pm 2,72

* - Note: compared to the reference group, $p \leq 0.05$.

However, it should be noted that in the group in which patients received Arecur suppositories, after the reduction of IL-8 expression, the "rebound effect" did not occur, that is, after 6 weeks and 3 months after the end of the course of treatment, the activity of this pro-oncogenic cytokine

remained relatively low. Also, when evaluating the activity of the anti-oncogenic cytokine IL-12, we came to the conclusion that its expression continues to remain at a relatively high level for a long period after treatment in the group of patients who received Arecur.



* - Note: compared to the reference group, $p \leq 0.05$.

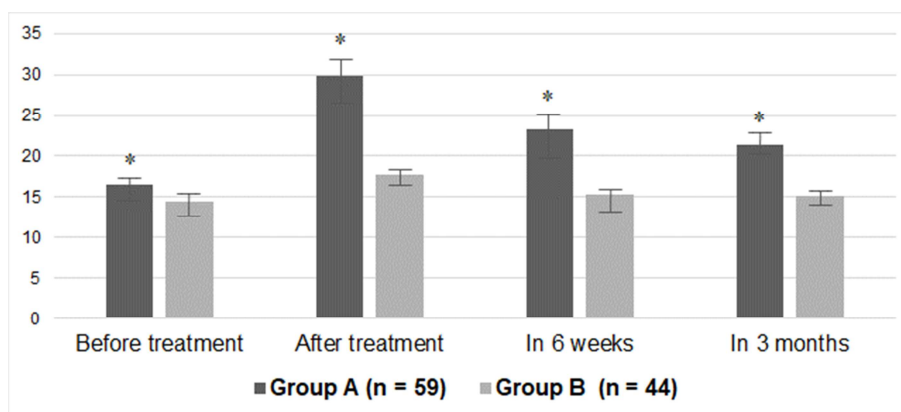
Figure 1. Comparison of Ki-67 expression level (H-Score) of cervical mucus in clinical monitoring groups.

Analysis of the level of expression of the cell proliferation marker Ki-67 in the clinical monitoring groups showed that

the proposed therapy schemes reduced the proliferative potential of the cervical epithelium. Nevertheless, it should

be noted that a more pronounced positive dynamic of the decrease in Ki-67 expression level was recorded in group A (Arecur), while the relatively low level of this indicator remained even after treatment. While in group B (interferon) after the predicted decrease in the proliferative potential of the epithelial layer immediately after treatment, an increase in the expression of Ki-67 was observed at the following control points (Figure 1).

The number of active cytotoxic lymphocytes in the cervical mucus in both observation groups predictably increased after the use of local immunotherapy. But it should be noted that compared to the reference group, the use of Arecur suppositories led to a more pronounced increase in the number of CD8+ cells, as well as to the preservation of the activity of these cells after 6 weeks and 3 months after the end of treatment. (Figure 2).



* - Note: compared to the reference group, $p \leq 0.05$.

Figure 2. Comparison of the number of cytotoxic CD8+ lymphocytes (cells/mm²) of cervical mucus in clinical monitoring groups.

It should also be noted that peptide immunotherapy with Arecur suppositories led to a more pronounced regression of clinical signs of grade 1 and 2 cervical intraepithelial neoplasia in comparison with the reference group of patients, as evidenced by the clinical cases below.

4.1. Clinical Case 1.*

Patient, 28 years old.

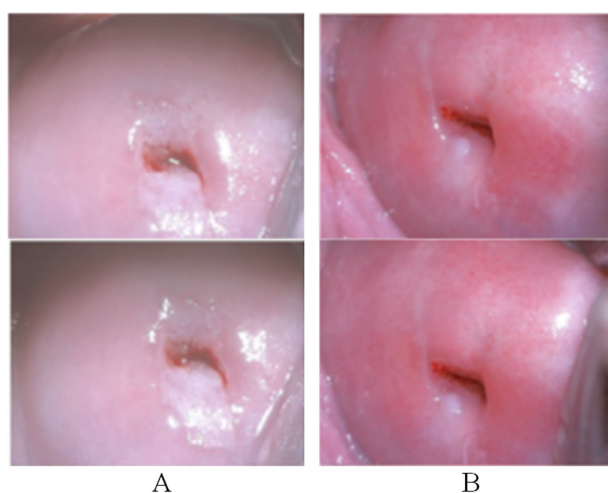


Figure 3. Patient 28 years old, A – before treatment (ASCUS), B – after treatment (NILM).

Cervical dysplasia CIN2 was diagnosed (cytology - ASCUS - Atypical Squamous Cells of Undetermined Significance - Bethesda), pro-oncogenic types of HPV-16, 18, 31, 33 were determined (Figure 3). Arecur suppositories are prescribed for a course of 20 days. After 6 weeks, viruses 16

and 18 PCR positive, 31 and 33 PCR negative. After 3 months, colposcopically and cytologically - positive dynamics, HPV is not detected, NILM (Negative for Intraepithelial Lesion or Malignancy - Bethesda) is diagnosed, clinical observation continues (Figure 3).

4.2. Clinical Case 2.**

Patient 32 years old.

She complained about discharge from the genital tract of a mucous nature, which has been bothering her for a year. When examining liquid cytology, it was diagnosed: squamous epithelial cells with undetermined atypia (ASCUS). The genotype of highly oncogenic HPV types 16, 18, 26, 31, 33 was diagnosed by PCR. A course of Arecur suppositories was prescribed in the regimen of 1 suppository per day for 20 days, the condition improved.

A control examination was carried out after a course of therapy after 6 weeks, which led to an improvement in the woman's quality of life, the absence of pathological secretions, and according to the results of liquid cytology, it was diagnosed: a negative test for intraepithelial lesions and malignant neoplasms (NILM). During the PCR study, highly oncogenic HPV types 16, 18, 26, 31, 33 were not detected.

4.3. Clinical Case 3.***

Patient, 44 years old.

Cervical dysplasia CIN2 was diagnosed, pro-oncogenic types of HPV-18 and 33 were determined, suppositories with interferon were prescribed for a course of 20 days. After 6 weeks, the virus was not identified, colposcopically and

cytologically - no positive dynamics were noted. After 3 months, in the absence of regression of clinical signs of CIN2 dysplasia, a decision was made to conduct CO2 laser vaporization of the focus.

4.4. Clinical Case 4.***

Patient, 34 years old.

Cervical dysplasia CIN2 – LSIL (Low-grade Squamous Intraepithelial Lesion – Bethesda) was diagnosed, pro-oncogenic types of HPV-16 and 18 were determined, Arecur suppositories were prescribed for a course of 20 days. After 6 weeks, HPV was not determined, colposcopically and cytologically - positive dynamics, CIN1 was diagnosed. After 3 months – regression of clinical signs of dysplasia, cervix without pathological changes: NILM (Figure 4).

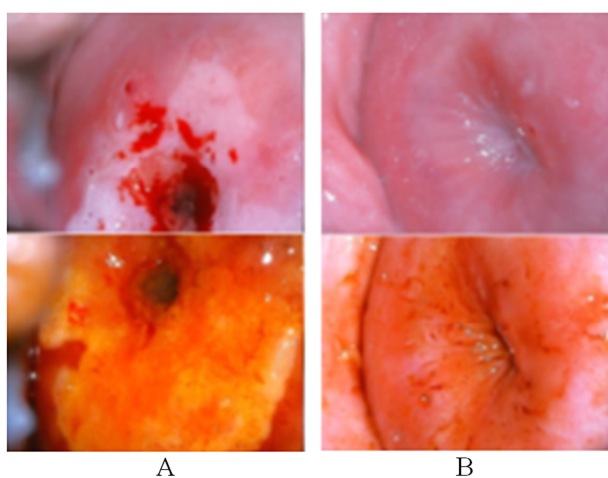


Figure 4. Patient 34 years old, A – before treatment (LSIL), B – after treatment (NILM).

4.5. Clinical Case 5.****

This clinical case was not included in the research group, but according to the authors, it deserves attention and is interesting for clinical practice.

Patient, 74 years old.

In March 2017, a diagnosis of cervical cancer was established

Preoperative radiation therapy

Wertheim's surgical approach was performed + removal of lymph nodes

+ postoperative radiation therapy.

Ultrasound 14.11.22: Uterus, appendages removed, adhesion process in the small pelvis, no pathological focal echo shadows. Cytological examination (PAP test) from 11/14/22 – HSIL. Arecur suppositories for 20 days.

Ultrasound 04.01.23 in the area of the scar infiltrative shadow without clear borders 38x34 mm (recurrence of the disease).

Cytological examination (PAP test) from 04.01.23 LSIL (CIN 1-2) in single cells.

Repeat course of Arecur for 20 days.

Ultrasound 20.02.23 Adhesion process in the small pelvis, no volumetric formations were detected. Cytological

examination (PAP test) from 20.02.23 LSIL (CIN 1).

Clinical observation continues.

* Department of Obstetrics and Gynecology of MI Pirogov VNMU, Vinnytsia, professor, Head of the Department, MD, PhD, O. V. Bulavenko

** Department of Obstetrics and Gynecology of ONMU, Odesa, MD, PhD, T. A. Lunko

*** Women's health center "Remedivin", Vinnytsia, MD, PhD, T. A. Fomina

**** Odesa Regional Oncology Dispensary, gynecologist-oncologist, MD, PhD, V. A. Zadorozhnyy

5. Discussion

It is common knowledge that the symptoms of cervical dysplasia usually appear in the last, "precancerous" stages. These are bleeding or the appearance of blood clots in secretions, delayed periods without objective reasons or pulling pains in the lower abdomen [25, 26]. In the early stages, none of this may be the case, so it is critically important to convey to women the importance of regular examinations by a gynecologist. If dysplasia has already been diagnosed, determining the presence of oncogenic papilloma viruses, their eradication if possible, and maintaining the local immune status of the cervix in order to prevent recurrence of the disease comes to the fore [27-29].

Since peptide immunotherapy in gynecology is presented in some modern scientific articles as an effective way of creating conditions for the elimination of pro-oncogenic viruses, as well as as a fundamentally new method of treatment of proliferative diseases [23, 24, 30, 31], it is relevant to study the effectiveness of peptides in the schemes of complex therapy of cervical dysplasia as a proven precancerous disease.

The ability of peptides to activate local immunity can be a decisive factor not only in the successful treatment of dysplasia, but also in the prevention of possible relapses of the disease [23, 24, 32, 33]. This effect can be evidenced by the fact that the cells on the epithelium of the cervix respond appropriately to the immunotherapeutic effect: they decrease the expression of pro-oncogenic cytokines and increase the expression of anti-oncogenic ones, as well as the activity of the Ki-67 proliferation factor decreases. An additional argument in favor of peptide immunotherapy for cervical dysplasia may be that it significantly increases the number of cytotoxic CD8 lymphocytes in cervical mucus compared to the results of a reference group of clinical monitoring.

It can be reasonably assumed that the results of the conducted research open up prospects for the use of peptides not only for immunotherapy of cervical dysplasia, but also for the management of other precancerous diseases in gynecology.

6. Conclusions

- 1) Immunotherapy of cervical dysplasia is effective in the context of elimination of pro-oncogenic types of human

papillomaviruses, influence on markers of inflammation and cell proliferation, and also according to assessment of activity of cytotoxic T-lymphocytes.

- 2) Studies have shown that immunotherapy of cervical dysplasia using Arecur suppositories demonstrated significantly better clinical results compared to the reference group.
- 3) Taking into account the obtained research results and the given clinical cases, the Arecur immunocorrector can be reasonably recommended as an immunological component in the treatment of cervical dysplasia (ASCUS and LSIL). And most importantly, Arecur has confirmed its anti-oncogenic effect as a drug of primary and secondary oncoprophylaxis - thanks to its proven effectiveness in the treatment of precancerous conditions and positive immunotherapeutic effect on the focus after tumor removal.

References

- [1] Al Roomy M, Chehadeh W, Al Awadhi R. Prediction of cervical cancer precursor lesions by quantitative methylation specific PCR: A retrospective study. *Cytopathology*. 2023 Jan 30. doi: 10.1111/cyt.13213. Epub ahead of print. PMID: 36715362.
- [2] Poniewierza P, Panek G. Cervical Cancer Prophylaxis-State-of-the-Art and Perspectives. *Healthcare (Basel)*. 2022 Jul 17; 10 (7): 1325. doi: 10.3390/healthcare10071325. PMID: 35885852; PMCID: PMC9319342.
- [3] Lehtinen M, Pimenoff VN, Nedjai B, Louvanto K, Verhoef L, Heideman DAM, El-Zein M, Widschwendter M, Dillner J. Assessing the risk of cervical neoplasia in the post-HPV vaccination era. *Int J Cancer*. 2023 Mar 15; 152 (6): 1060-1068. doi: 10.1002/ijc.34286. Epub 2022 Oct 10. PMID: 36093582.
- [4] D'Oria O, Corrado G, Laganà AS, Chiantera V, Vizza E, Giannini A. New Advances in Cervical Cancer: From Bench to Bedside. *Int J Environ Res Public Health*. 2022 Jun 9; 19 (12): 7094. doi: 10.3390/ijerph19127094. PMID: 35742340; PMCID: PMC9222371.
- [5] Yadav C, Yadav R, Chhabra R, Nanda S, Ranga S, Kadian L, Ahuja P. Overview of genetic and epigenetic regulation of human papillomavirus and apoptosis in cervical cancer. *Apoptosis*. 2023 Jan 18. doi: 10.1007/s10495-023-01812-w. Epub ahead of print. Erratum in: *Apoptosis*. 2023 Feb 9; PMID: 36652131.
- [6] Luan H. Human papilloma virus infection and its associated risk for cervical lesions: a cross-sectional study in Putuo area of Shanghai, China. *BMC Womens Health*. 2023 Jan 20; 23 (1): 28. doi: 10.1186/s12905-023-02166-w. PMID: 36658539; PMCID: PMC9854058.
- [7] Qin D, Bai A, Xue P, Seery S, Wang J, Mendez MJG, Li Q, Jiang Y, Qiao Y. Colposcopic accuracy in diagnosing squamous intraepithelial lesions: a systematic review and meta-analysis of the International Federation of Cervical Pathology and Colposcopy 2011 terminology. *BMC Cancer*. 2023 Feb 23; 23 (1): 187. doi: 10.1186/s12885-023-10648-1. PMID: 36823557; PMCID: PMC9951444.
- [8] Becker S, Jonigk D, Luft A, Dübbel L, Werlein C, Malik E, Schild-Suhren M. COVID-19 can lead to rapid progression of cervical intraepithelial neoplasia by dysregulating the immune system: A hypothesis. *J Reprod Immunol*. 2022 Dec; 154: 103763. doi: 10.1016/j.jri.2022.103763. Epub 2022 Nov 9. PMID: 36399874; PMCID: PMC9645588.
- [9] Sarma U, Das GC, Sarmah B. Predictive Value of Marker of Proliferation Ki-67 and Cell Cycle Dependent Protein kinase Inhibitor P16INK4a in Cervical Biopsy to Determine Its Biological Behaviour. *Asian Pac J Cancer Prev*. 2021 Jul 1; 22 (7): 2237-2241. doi: 10.31557/APJCP.2021.22.7.2237. PMID: 34319047; PMCID: PMC8607082.
- [10] Vahedpour Z, Abedzadeh-Kalahroudi M, Sehat M, Piroozmand A, Memar M. Comparison of Cervical Levels of Interleukins-6 and -8 in Patients with and without Cervical Intraepithelial Neoplasia. *Asian Pac J Cancer Prev*. 2021 Apr 1; 22 (4): 1225-1230. doi: 10.31557/APJCP.2021.22.4.1225. PMID: 33906316; PMCID: PMC8325114.
- [11] Osiagwu DD, Azenabor AE, Osijirin AA, Awopetu PI, Oyegbami FR. Evaluation of interleukin 8 and interleukin 10 cytokines in liquid based cervical cytology samples. *Pan Afr Med J*. 2019 Mar 26; 32: 148. doi: 10.11604/pamj.2019.32.148.16314. PMID: 31303919; PMCID: PMC6607241.
- [12] Bonin-Jacob CM, Almeida-Lugo LZ, Puga MAM, Machado AP, Padovani CTJ, Noceti MC, et al. (2021) IL-6 and IL-10 in the serum and exfoliated cervical cells of patients infected with high-risk human papillomavirus. *PLoS ONE* 16 (3): e0248639. <https://doi.org/10.1371/journal.pone.0248639>
- [13] Litwin TR, Irvin SR, Chornock RL, Sahasrabudhe VV, Stanley M, Wentzensen N. Infiltrating T-cell markers in cervical carcinogenesis: a systematic review and meta-analysis. *Br J Cancer*. 2021 Feb; 124 (4): 831-841. doi: 10.1038/s41416-020-01184-x. Epub 2020 Dec 1. PMID: 33257839; PMCID: PMC7884592.
- [14] Carrero YN, Callejas DE, Mosquera JA. In situ immunopathological events in human cervical intraepithelial neoplasia and cervical cancer: Review. *Transl Oncol*. 2021 May; 14 (5): 101058. doi: 10.1016/j.tranon.2021.101058. Epub 2021 Mar 4. PMID: 33677234; PMCID: PMC7937982.
- [15] Zhang L, Mao Z, Lai Y, Wan T, Zhang K, Zhou B. A review of the research progress in T-lymphocyte immunity and cervical cancer. *Transl Cancer Res*. 2020 Mar; 9 (3): 2026-2036. doi: 10.21037/tcr.2020.01.33. PMID: 35117549; PMCID: PMC8797462.
- [16] Desravines N, Miele K, Carlson R, Chibwesha C, Rahangdale L. Topical therapies for the treatment of cervical intraepithelial neoplasia (CIN) 2-3: A narrative review. *Gynecol Oncol Rep*. 2020 Jul 2; 33: 100608. doi: 10.1016/j.gore.2020.100608. PMID: 32685652; PMCID: PMC7356206.
- [17] Muntinga CLP, de Vos van Steenwijk PJ, Bekkers RLM, van Esch EMG. Importance of the Immune Microenvironment in the Spontaneous Regression of Cervical Squamous Intraepithelial Lesions (cSIL) and Implications for Immunotherapy. *J Clin Med*. 2022 Mar 5; 11 (5): 1432. doi: 10.3390/jcm11051432. PMID: 35268523; PMCID: PMC8910829.
- [18] Moretta A, Scieuzo C, Petrone AM, Salvia R, Manniello MD, Franco A, Lucchetti D, Vassallo A, Vogel H, Sgambato A, Falabella P. Antimicrobial Peptides: A New Hope in Biomedical and Pharmaceutical Fields. *Front Cell Infect Microbiol*. 2021 Jun 14; 11: 668632. doi: 10.3389/fcimb.2021.668632. PMID: 34195099; PMCID: PMC8238046.

- [19] Haidari H, Melguizo-Rodríguez L, Cowin AJ, Kopecki Z. Therapeutic potential of antimicrobial peptides for treatment of wound infection. *Am J Physiol Cell Physiol*. 2023 Jan 1; 324 (1): C29-C38. doi: 10.1152/ajpcell.00080.2022. Epub 2022 Nov 21. PMID: 36409176.
- [20] Mulkern AJ, Oyama LB, Cookson AR, Creevey CJ, Wilkinson TJ, Olleik H, Maresca M, da Silva GC, Fontes PP, Bazzolli DMS, Mantovani HC, Damaris BF, Mur LAJ, Huws SA. Microbiome-derived antimicrobial peptides offer therapeutic solutions for the treatment of *Pseudomonas aeruginosa* infections. *NPJ Biofilms Microbiomes*. 2022 Aug 29; 8 (1): 70. doi: 10.1038/s41522-022-00332-w. PMID: 36038584; PMCID: PMC9424236.
- [21] Jafari A, Babajani A, Sarrafi Forooshani R, Yazdani M, Rezaei-Tavirani M. Clinical Applications and Anticancer Effects of Antimicrobial Peptides: From Bench to Bedside. *Front Oncol*. 2022 Feb 23; 12: 819563. doi: 10.3389/fonc.2022.819563. PMID: 35280755; PMCID: PMC8904739.
- [22] Kordi M, Borzouyi Z, Chitsaz S, Asmaei MH, Salami R, Tabarza M. Antimicrobial peptides with anticancer activity: Today status, trends and their computational design. *Arch Biochem Biophys*. 2023 Jan 1; 733: 109484. doi: 10.1016/j.abb.2022.109484. Epub 2022 Dec 5. PMID: 36473507.
- [23] Kurchenko A et al., Anti-recurrent Immunocorrection in Gynecology Andrology and Proctology. *Int J of Immunology*. 2020. Vol. 8 (1): 1-8.
- [24] Zakharenko N et al. Prospects for the Treatment of Endometriosis: The Effect of Immune Peptides on the Reactivation of Immune Surveillance over Ectopic Endometrial Cells. *Journal of Gynecology and Obstetrics*. Vol. 8, No. 5, 2020, 148-153.
- [25] Stoler MH, Wright TC Jr, Parvu V, Yanson K, Cooper CK, Andrews JA. Detection of high-grade cervical neoplasia using extended genotyping: Performance data from the longitudinal phase of the Onclarity trial. *Gynecol Oncol*. 2023 Mar; 170: 143-152. doi: 10.1016/j.ygyno.2023.01.004. Epub 2023 Jan 22. PMID: 36682092.
- [26] Choi S, Ismail A, Pappas-Gogos G, Boussios S. HPV and Cervical Cancer: A Review of Epidemiology and Screening Uptake in the UK. *Pathogens*. 2023 Feb 11; 12 (2): 298. doi: 10.3390/pathogens12020298. PMID: 36839570; PMCID: PMC9960303.
- [27] Hughes KC, Herring TA, Song JN, Gately RV, Przybyl LM, Ogilvie RP, Simon K, Bhuyan PK, Kyrgiou M, Seeger JD. Cervical High-Grade Squamous Intraepithelial Lesion Burden and Standard of Care Treatment Effectiveness and Safety in the United States, 2008-2018: The EACH-WOMAN Project. *J Low Genit Tract Dis*. 2023 Apr 1; 27 (2): 105-112. doi: 10.1097/LGT.0000000000000719. Epub 2023 Feb 23. PMID: 36815642.
- [28] Viveros-Carreño D, Fernandes A, Pareja R. Updates on cervical cancer prevention. *Int J Gynecol Cancer*. 2023 Mar 6; 33 (3): 394-402. doi: 10.1136/ijgc-2022-003703. PMID: 36878567.
- [29] Kaur S, Sharma LM, Mishra V, Goyal MGB, Swasti S, Talele A, Parikh PM. Challenges in Cervical Cancer Prevention: Real-World Scenario in India. *South Asian J Cancer*. 2023 Feb 25; 12 (1): 9-16. doi: 10.1055/s-0043-1764222. PMID: 36851931; PMCID: PMC9966165.
- [30] Jiang G, Wu Q, Li B. Evaluation of immunotherapy efficacy in gynecologic cancer. *Front Immunol*. 2023 Jan 31; 14: 1061761. doi: 10.3389/fimmu.2023.1061761. PMID: 36793735; PMCID: PMC9922993.
- [31] Tang M, Cai JH, Diao HY, Guo WM, Yang X, Xing S. The progress of peptide vaccine clinical trials in gynecologic oncology. *Hum Vaccin Immunother*. 2022 Nov 30; 18 (5): 2062982. doi: 10.1080/21645515.2022.2062982. Epub 2022 Jun 10. PMID: 35687860; PMCID: PMC9450897.
- [32] Liu X, Peng J, He J, Li Q, Zhou J, Liang X, Tang S. Selection and identification of novel peptides specifically targeting human cervical cancer. *Amino Acids*. 2018 May; 50 (5): 577-592. doi: 10.1007/s00726-018-2539-1. Epub 2018 Feb 12. PMID: 29435721.
- [33] Ahmed S, Khan H, Fakhri S, Aschner M, Cheang WS. Therapeutic potential of marine peptides in cervical and ovarian cancers. *Mol Cell Biochem*. 2022 Feb; 477 (2): 605-619. doi: 10.1007/s11010-021-04306-y. Epub 2021 Dec 2. PMID: 34855045.